

APPLICATION OF IMAGE ANALYSIS FOR CLINICAL EVALUATION OF FACIAL STRUCTURES

Pavel Kasal, Patrik Fiala, Lubomír Štěpánek, Jan Měšťák, Stanislav Machač, Jana Duspivová

Summary:

A somatometric analysis of the digitized image and a subsequent confrontation of the gained information with the standard parameters create a methodical approach to evaluate morphological structures of face and their objectification. Application of methods of geometric morphology allowing multidimensional evaluation of structural data is a perspective in this field. The mentioned methodologies were used for planning of rhinoplasty optimization on the basis of facial profile type, assessment of nasolabial folds symmetry as a related screening symptom of spinal asymmetries and also for evaluation of facial expressions while expressing particular emotions as a basis for subsequent standardization of facial surgeries effect.

Souhrn:

Metodickým přístupem pro hodnocení morfologických struktur obličeje a jejich objektivizaci je somatometrická analýza digitalizovaného obrazu a následná konfrontace získané informace se standardními parametry. Perspektivou v této oblasti je uplatnění metod geometrické morfometrie, umožňující vícerozměrné hodnocení strukturálních dat. Uvedené metodologie byly využity pro plánování optimalizace rhinoplastik na základě typu obličejového profilu, posuzování symetrie nazolabiálních rýh jako průvodního screeningového příznaku u asymetrií páteře a dále pak hodnocení mimiky při jednotlivých emočních výrazech jako základ pro následnou standardizaci efektu obličejových operací.

Key words:

Morphometry, Rhinoplasty, Scoliosis, Facial Expression

1. Rhinoplasty effect model

The surgical correction of nasal shape - rhinoplasty is one of the most difficult interventions of facial surgery. The profile attractiveness is determined primarily by nasofrontal and nasolabial angle, nasal prominence and nostril width. The degree of success of surgery is evaluated by means of the mentioned parameters changes and also on the basis of a scale evaluation made by panel of evaluators. It is crucial to evaluate an esthetic optimum by virtue of the given parameters; however, a design of each individual correction is also influenced by each individual somatotype. The main issue is that the result depends on individual combination of particular factors within each somatotype, as there is not any particular "optimal nose". The context with a forehead, chin and lips contour employs in a facial profile (3, 6, 7).

Methods: The software, which on the basis of morphometric points - landmarks (LM) allows the user to create a digital visualization of surgical corrections made within rhinoplasty, was created.

Results: The photograph of a patient's profile is uploaded into the program. User selects option of manual or automatic LM shift. As a first LM, user selects a place on a forehead which serves as a point assisting to a grid creation where a modification of the original picture takes place. As a second LM, the nasal root is selected, and then the highest point of its ridge, the nasal tip and, as the last one, again the auxiliary LM, the vertex of the angle between nose and lip. If the user selects a manual correction, s/he can arbitrarily shift all the LMs on the whole grid by a mouse. If an automatic correction is selected, it is possible to select direction and size of shift also. The size is determined by figures defined in advance or a particular number of pixels (Fig. 1, 2).

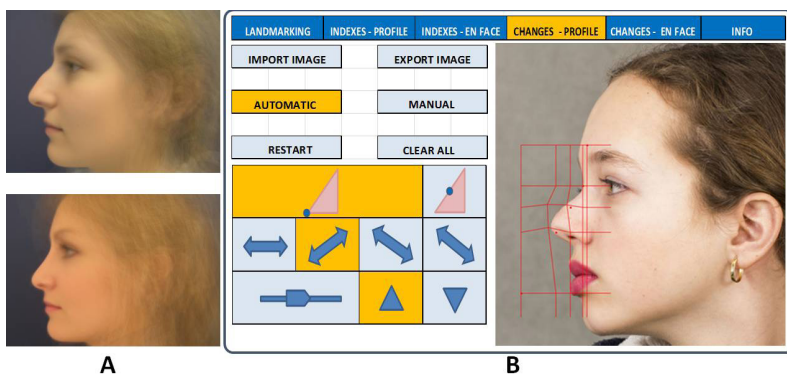


Figure 1 – A) Summarization of pictures of fifty female patients before rhinoplasty and after it. B) Software for digital modification of a profile.




Figure 2 – Modification of initial photograph in individual aspects.

Discussion: The program enables projection of anticipated final result of surgery for a particular person. Yet published types of software designated for projection of anticipated rhinoplasty effect simulate final appearance of profile after a one-sided modification of basic nasal dimensions of the particular person. This program allows simultaneous combination of dimensions within 3 directions (ridge length, basis and nasal ridge convexity) at the same time. Moreover, it does not require manual operating of changes direction and enables quantified gradual modifications also. Automatic search for source points needed for necessary projection of the initial contour (nasion, nasal tip and alar-sidewall) is a next stage of development.

2. Nasolabial folds symmetry and scoliosis

The progress of scoliosis during ontogeny of a child can be slow; it can be manifested as a faulty posture only and therefore it can escape from the attention of pediatrician. The diagnosis at a specialized orthopedic department and subsequent adequate cure are sometimes postponed from the mentioned reasons. In this respect, it is useful to employ a simple screening method for specialized examination indication as a supplement to symptomatic complex of this disease.

Recently, findings of changes of facial symmetry, mainly asymmetry of mandible, connected to scoliosis were published at stomatological departments. The cause could reside in malfunctions of cervical spine symmetry which manifest in a subsequent malfunction of face evolution also (2, 8). In that context, it was assumed that this situation could be demonstrated in facial marks also. On the basis of this assumption we proceeded to a morphometric examination of a face. Due to the fact that the changes of facial symmetry deepen in response to facial expressions of more intensive emotions, the pictures of standardized smile were evaluated. Comparison of nasolabial folds length ratio was chosen for objectivization of facial expression symmetry.

Methods: A group of 11 female patients with more serious stage of idiopathic scoliosis with medically indicated corset and a group of 14 healthy female probands as a control group were examined. In order to highlight nasolabial folds, pictures of middle-intensive smiles showing maximally the upper edge of teeth were taken.

Morphometric method: The total distance of morphometric points for peak, curve and lower part of nasolabial fold was assessed and the aspect ratio coming always from the higher figure was calculated. The result of the assessment is asymmetry criterion expressed by aspect ratio neglecting laterality (Fig. 3).

Results: Controls: AVG=1,06 SD= 0,06 CI5%= 0,03; Scoliosis: AVG=1,7 SD=0,52 CI5%=0; t-test: 0,002. Values for limit 1,2: Sensitivity=0,81 Specificity=1 Efficiency=0,92

At the same time, the correlation between scoliosis asymmetry extent and visibility of asymmetry of nasolabial folds and relationship of these parameters in terms of their laterality was assessed. According to preliminary results,




Figure 3 – A) Landmarking of nasolabial folds;
B) Smile and asymmetry demonstration in case of scoliosis.

the mentioned relationship is on the borderline of significance, what can be related to rather small amount of probands.

Discussion: According to preliminary results, the nasolabial folds asymmetry in cases of scoliosis compared to normal population is significantly higher. Relatively high efficiency of the method was proven within the determined limits of asymmetry ratio in the examined set. According to the preliminary results, the mentioned symptom can be used for indicative examination of faulty posture of children.

3. Evaluation of after-surgery changes of facial expressions

In case of some facial operations, the facial expression can be modified by surgical intervention. As a method for assessment of this aspect we have chosen dynamic changes of facial muscles. Positive emotions in the form of smile's scales, in terms of its intensity and type, were used for this purpose. The intensity was evaluated as per the height and width of lip aperture following the position of teeth occlusion line. The typology of smile was specified according to the type of its motivation into the following categories representing various involvements of facial muscles:

Communication: Formal, Friendly, Warm; Curious, Communicative, Surprised; Disagreeing, Indecisive, Affirmative.

Relationships: Apologetic, Innocent, Enamoured; Empathetic, Admiring, Thankful; Self-confident, Seductive, Teasing.

Situations: Blissful, Pleased, Joyful; Amused, Cheered up, Laugh; Hopeful, Impatient, Enthusiastic (Fig. 4).

Methods: The examined group expressed instructions for particular types of smiles on the basis of motivational sentences. Examples: Formal - "Good morning, Mr. Smith!", Friendly - "Hi, John!", Warm - "Wow, you've come!". Afterwards, the composite (morphing) pictures summarizing all the pictures for the given type of smile into one resultant image were created. For evaluation it was used a method of geometric morphometrics enabling standardization of multidimensional relationship for functions of particular groups of facial muscles, including affinity of resultant expressions (Fig. 5, 6).

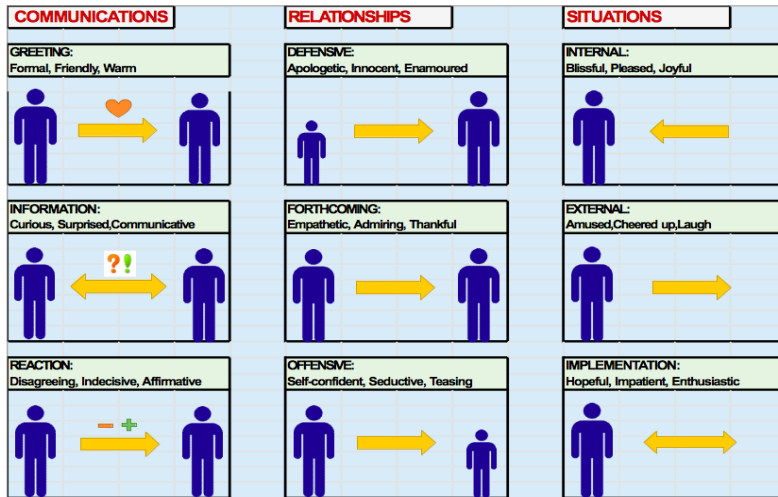


Figure 4 – Smile classification according to type of motivation

Results: The affinity range of the mentioned facial expressions and their group stratification was determined by the method of geometric morphometrics. There are evident differences in the width of eye apertures, noticeability of nasolabial folds and fullness of lower lip on the sample sequence of pictures (conventional-honest-empathetic). Evaluation by the group of evaluators also determined the score of attractiveness as follows: amused, joyful, honest, conventional, seductive, blissful, empathetic, excited, innocent.

By the method k-means cluster analysis the existence of clusters which



Figure 5 – A) Composite image of type and changes of facial expression intensity. B) Morphing image on the basis of motivation instructed: Formal smile – „Good morning, Mr. Smith!“, Honest smile – „Hi, John!“, Empathetic smile – „Oh, what a cute kitty!“.

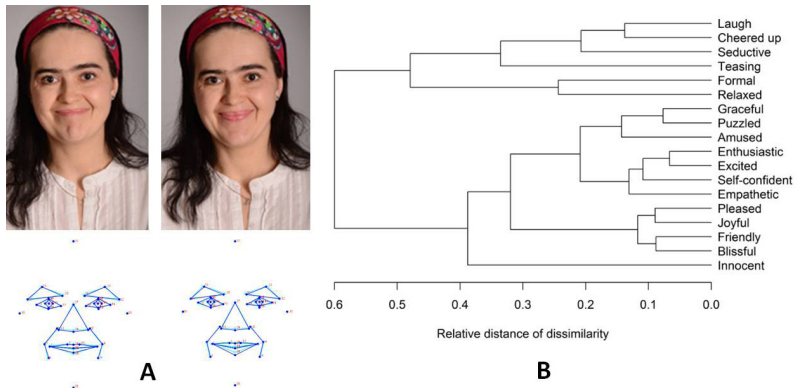


Figure 6 – A) Evaluation of facial expression depicted by geometric morphometrics. B) Cluster analysis – dendrogram with dissimilarity of smiles.

optimally characterize facial expressions when smile occurs was assessed. It was proven that there exist approximately 6 relevant, closely related groups defined by a combination of facial marks. Further, dendrograms for assessment of affinity extent were developed within the cluster analysis. Particular types of smiles and facial structures which are employed within these facial expressions were assessed, including the relative distance of dissimilarity.

Discussion: Typology of individual categories enables standardization of methods of facial expression changes assessment for the said purposes, including optimization of their evaluation (1, 4, 5). The perspective resides in evaluation of facial expressions after cosmetic surgery procedures to assess individual operational procedures in terms of subsequent postoperative changes that may affect it.

Bibliography

- [1.] Ekman P., Friesen W.: *Unmasking the Face. Recognizing Emotions from facial expressions.* Malor Books, Cambridge 2003
- [2.] Hong JY1, Suh SW, Modi HN, Yang JH, Hwang YC, Lee DY, Hur CY, Park YH.: *Correlation between facial asymmetry, shoulder imbalance, and adolescent idiopathic scoliosis.* *Orthopedics.* 2011 Jul14;34(6):187.
- [3.] Khosravanifard B1, Rakhshan V, Raesi E.: *Factors influencing attractiveness of soft tissue profile.* *Oral Surg Oral Med Oral Pathol Oral Radiol.* 2013 Jan;115(1):29-37
- [4.] Lin A1, Braun T, McNamara JA Jr, Gerstner GE.: *Esthetic evaluation of dynamic smiles with attention to facial muscle activity.* *Am J Orthod Dentofacial Orthop.* 2013 Jun; 143(6):819-27
- [5.] Medlej J.: *Emotions and Facial Expression.* <http://majnouna.deviantart.com/art/Emotions-and-Facial-Expression-47118559>
- [6.] Pearson D., Adamson P.: *The Ideal Nasal Profile Rhinoplasty Patients vs the General Public.* *Arch Facial Plast Surg.* 2004;6(4):257-262

[7.] Valenzano D., Mennuccia A., Tartarelli G.a, Cellerino A.: Shape analysis of female facial attractiveness. *Vision Research*, Volume 46, Issues 8–9, April 2006, Pages 1282–129

[8.] Zhou S1, Yan J, Da H, Yang Y, Wang N, Wang W, Ding Y, Sun S.: A correlational study of scoliosis and trunk balance in adult patients with mandibular deviation. *PLoS One*. 2013;8(3):e59929

Contact:

Doc. MUDr. Pavel Kasal, CSc

Bc. Patrik Fiala

MUDr. Lubomír Štěpánek

Department of Biomedical Informatics

Faculty of Biomedical Engineering

Czech Technical University, Prague

e-mail: pavel.kasal@fbmi.cvut.cz

Tel.: 224358493

Doc. MUDr. Jan Měšťák, CSc

Department of Plastic Surgery

1st Faculty of Medicine

Charles University, Prague.

Mgr. Stanislav Machač

Bc. Jana Duspivová

Department of Rehabilitation

and Sports Medicine

2nd Faculty of Medicine

Charles University, Prague